

Memory for Familiar Environments Learned in the Remote Past: fMRI Studies of Healthy People and an Amnesic Person With Extensive Bilateral Hippocampal Lesions

R. Shayna Rosenbaum,^{1,2*} Gordon Winocur,^{2,3,4} Cheryl L. Grady,^{2,3} Marilyne Ziegler,³ and Morris Moscovitch^{2,3}

ABSTRACT: Preserved remote spatial memory in amnesic people with bilateral hippocampal damage, including the well-studied case K.C., challenges spatial theories, which assume that the hippocampus is needed to support all allocentric spatial representations, old or new. It remains possible, however, that residual hippocampal tissue is functional and contributes to successful performance. Here, we examine brain activity with fMRI during the retrieval of spatial information in K.C. and in healthy controls using landmark and route stimuli from a premorbidly familiar neighborhood that K.C. can navigate normally. In all participants, activity was found in the parahippocampal cortex, but not in the hippocampus itself, during all navigational tasks on which K.C. performs well, even though part of his hippocampus remains viable. The opposite pattern was observed on a house recognition task, which is inconsequential to navigation, and on which K.C. performed poorly. On that task, K.C. recruited the right hippocampus presumably because even “familiar” houses were treated as novel by him, whereas controls recruited occipitotemporal cortex, including parahippocampal cortex. The distinction between recent and remote memory, therefore, may apply as much to spatial theories of hippocampal function as it does to theories emphasizing the role of the hippocampus in other types of explicit memory. © 2007 Wiley-Liss, Inc.

KEY WORDS: retrograde amnesia; medial temporal lobe; spatial memory; neuroimaging; patient K.C.

INTRODUCTION

Findings of temporally graded retrograde amnesia following hippocampal damage have led to the widespread belief that with time, explicit, or declarative memories no longer depend on the hippocampus for their maintenance and recovery (Squire, 1992; Nadel and Moscovitch, 1997). With respect to spatial memory, the influential cognitive map theory of hippocampal function posits that the hippocampus is crucial for maintaining and operating on internal, allocentric representations necessary for navigation, whether they are old or newly formed (O’Keefe and Nadel, 1978).

Consistent with traditional spatial theories, the role of the hippocampus in acquiring spatial memory in humans and in nonhuman organisms is beyond dispute (O’Keefe and Nadel, 1978; Smith and Milner, 1981; Morris et al., 1982), though interpretation of the evidence has been debated for years (Cohen and Eichenbaum, 1993). What is less clear is whether the hippocampus is needed for memory and navigation of well-learned environments. Deficits in spatial memory and navigation of familiar environments are rarely, if ever, associated with lesions confined to the hippocampus. Instead, the areas most associated with such deficits are the posterior parietal lobe, parahippocampal cortex, posterior cingulate/retrosplenial cortex, and occipitotemporal cortex (Aguirre and D’Esposito, 1999). Systematic studies of two patients, K.C. and E.P., who have extensive bilateral damage to the hippocampus (Teng and Squire, 1999; Rosenbaum et al., 2000), are consistent with the literature. Although the patients are incapable of new spatial learning when tested on either artificial table-top or natural, large-scale environments, they perform normally on a wide range of spatial-topographical measures based on a neighborhood that was learned long ago, even if it had not been experienced in decades, as with E.P. The only test on which K.C. was impaired was one that required him to identify houses (e.g., next door, belonging to friends) by their appearance. This may be viewed as consistent with findings from a more recent study of a third case, T.T., with bilateral hippocampal damage who was once a London taxi driver (Maguire et al., 2006). Like E.P. and K.C., T.T. also showed complete preservation on static tests of remote spatial relations contained within London as well as on dynamic tests based on a virtual reality (VR) simulation of the same environment. However, he was found impaired on VR tests requiring navigation through nonmajor thoroughfares, known as B-routes, which are more dense and less distinguishable from each other and, in this sense, may require more detailed representations to support navigation than major A-routes. Together, the results may suggest that what is retained are skeletal or schematic spatial representations mediated by extra-hippocampal structures. These include allocentric representations of the neighborhood, which are adequate for navigation but not for detailed re-experiencing of the envi-

¹ Department of Psychology, York University, Toronto, Ontario, Canada;

² Rotman Research Institute, Baycrest Centre for Geriatric Care, Toronto, Ontario, Canada; ³ Department of Psychology, University of Toronto, Toronto, Ontario, Canada; ⁴ Department of Psychology, Trent University, Peterborough, Ontario, Canada

Grant sponsor: Canadian Institutes of Health Research (CIHR); Grant number: MOP-135808.

*Correspondence to: R. Shayna Rosenbaum, Department of Psychology, York University, 4700 Keele St., Toronto, ON, M3J 1P3, Canada.

E-mail: shaynar@yorku.ca

Accepted for publication 17 July 2007

DOI 10.1002/hipo.20354

Published online 12 September 2007 in Wiley InterScience (www.interscience.wiley.com).

ronment in all its richness (Rosenbaum et al., 2000, 2001; Winocur et al., 2005).

These conjectures have been confirmed in a recent neuroimaging study of healthy people on the very same tests administered to the patients, though the environment used was the downtown core of a large city (Toronto) rather than their home neighborhood (Rosenbaum et al., 2004a). Activation was found in parahippocampal cortex, posterior cingulate/retrosplenial cortex, and occipitotemporal cortex (Aguirre and D'Esposito, 1999), but not the hippocampus on any of the tests. We also found that allocentric spatial knowledge of the downtown core was spared in a person with probable Alzheimer's disease whose hippocampus had atrophied bilaterally by more than 50% (Rosenbaum et al., 2005a). The possibility remains, however, that spatial memory for the grid-like downtown core is different than memory for a home neighborhood that is a little more tortuous. Moreover, K.C. has some hippocampal tissue remaining, and it may be the case that intact spatial memory for his neighborhood is dependent on this hippocampal remnant as has been shown in the developmental amnesic patient Jon during retrieval of episodic memories (Maguire et al., 2001).

If healthy and amnesic participants perform equally well on tests of remote spatial memory, but only the healthy participants show hippocampal activation, it would indicate that the hippocampus is involved but is not necessary for spatial representations of familiar neighborhoods. The absence of hippocampal activation even in healthy participants, however, would suggest that the hippocampus is not involved at all in those spatial tests. If that is the case, finding structurally intact tissue that is similarly active in K.C. and in controls will help to indicate which extra-hippocampal regions are sufficient for supporting remote spatial memory, allocentric and otherwise. To distinguish among these alternatives, we investigated brain activation during tests of spatial memory in neurologically intact individuals and in K.C.

We expect a pattern of activation in the network of extra-hippocampal structures identified in the earlier neuroimaging and lesion studies described earlier on remote spatial memory tasks on which K.C. performs normally. These include mental navigation tests that have allocentric components (tests of distance and direction) or are more egocentric in nature (sequencing landmarks and navigating along routes) and tests of visual identity of neighborhood landmarks (perception and recognition). Although not crucial for navigation, we also included a recognition test of neighborhood houses, which do not serve as landmarks, because K.C. was impaired on them relative to controls, and we wished to know the source of his deficit.

MATERIALS AND METHODS

Participants

We used fMRI to explore the neural network underlying K.C.'s success at retrieving from remote memory spatial representations drawn from real-life topographical experiences with his neighborhood. The following tasks were used: perception and recognition of landmark appearance, judgment of distance

and of direction between landmarks in a vector task, sequencing landmarks in the order that they are passed along a route, imagining a direct route between landmarks, and negotiating a detour when the most direct route is blocked. fMRI was also used to investigate K.C.'s remote memory loss for visual details contained within an otherwise familiar environment. Patterns of activity in K.C. were compared to those of control participants with extensive experience navigating in the neighborhood on which tasks were based, many of whom had moved away at the onset of K.C.'s amnesia and had not visited since. All participants gave informed written consent to participate in the fMRI investigation and received monetary compensation, with approval from the Baycrest and the Sunnybrook Health Sciences Centre Ethics Committees.

Patient K.C.

K.C. was 51 years old at the time of the experimental investigation. He is a right-handed man with 16 yrs of education. In 1981, he suffered a closed head injury from a motorcycle accident that left him with a profound anterograde and retrograde amnesia. His inability to commit new information to explicit memory is clear in his failure to recall the floor plan of the library where he has worked since 1997, though his implicit memory for sorting books according to the Dewey decimal system is retained from that time. K.C. also appears to be like any other healthy individual with respect to his store of semantic facts about himself and the world and procedural skills that were acquired in the first 30 yrs of his life. What makes him different, even from many amnesic patients, is his inability to recollect a specific event relating to any one of these facts that he witnessed or participated in or to travel mentally to the specific time and place in which a skill was first learned. He can describe the shortest route between, and the layout of, his house and summer cottage without any recollection of a single event that occurred at either of these places. Not even an intact corpus of mental faculties such as perception, language, and reasoning skills would enable K.C. to relive an ever-growing personal episodic past or invent possible future events in which he might participate.

Of particular relevance to the current experimental investigation, significant neurological signs from a March 2003 exam included a right homonymous hemianopia involving the upper field with lower quadrant and macular sparing, and bilateral optic disk pallor from glaucoma that has been treated since just after his accident (Rosenbaum et al., 2005b). Visual acuity was most recently 20/40 on the right and less than 20/400 on the left, and K.C. could see finger movement at 6 feet and identify large letters at 3 feet. Evidence of progressive visual loss in the left eye is due in large part to his glaucoma; his corrected vision in the right eye was still within normal limits. Importantly, visual impairments do not appear to affect his visual matching or descriptions of colors or objects contained in photographs. Strength in the hands was normal except for some decrease in dexterity on the right. Overall, comparison with previous neurological examinations indicates that K.C.'s neuro-

logical status has remained largely stable since his accident, consistent with the stability of results from extensive neuropsychological testing and structural imaging.

Detailed neuropsychological examination conducted in 1996 has been reported elsewhere (Rosenbaum et al., 2000; Westmacott et al., 2001), and reassessment in 2003 confirmed that earlier scores generally reflect K.C.'s current level of cognitive function (Rosenbaum et al., 2005b). Specifically, mental status on the Dementia Rating Scale (Mattis, 1988) revealed a score of 125/144, which is above the cutoff for dementia, with most points lost on the memory subscale. The only exception was an IQ score of 99 on the Full, Verbal, and Performance scales of the Wechsler Abbreviated Scale of Intelligence (WASI; Wechsler, 1999), which represents improved nonverbal ability from the 1996 assessment, and is likely due to better management of K.C.'s glaucoma in more recent years. Otherwise, K.C.'s visuospatial, language, and executive functions have remained stable, and he continues to exhibit profound impairment on tests tapping immediate and delayed anterograde memory for verbal and nonverbal material. Briefly, identification of line drawings of common objects on the Boston Naming Test was well within normal limits (57/60), and his performance was in the average range on a test of semantic fluency (scaled score of 10) and on the vocabulary subtest of the WASI (scaled score of 9). His visuospatial construction on the block design test of the WASI was normal (scaled score of 9), and his copy of the Rey-Osterrieth complex figure received a perfect score. K.C. also performed well on verbal and nonverbal tests of abstract reasoning (scaled score of 11 on WASI similarities and matrix reasoning subtests) and on a test of concept formation and mental flexibility (6 categories achieved on Wisconsin Card Sorting Test). Finally, working memory performance was within normal limits on both forward and backward digit span tests of the Wechsler Memory Scale-III (WMS-III; scaled score of 12).

With respect to memory, K.C. exhibits profound impairment on standardized anterograde tests. He received a scaled score of 4 for the immediate recall condition and a scaled score of 1 for the delayed condition of the WMS-III logical memory subtest, and he received a score of 0 on delayed memory for the Rey-Osterrieth complex figure. He also performed at chance levels on the words and faces subscales of the Warrington Recognition Memory Test. Memory performance in the immediate and delayed conditions of the California Verbal Learning Test was likewise impaired (acquisition: $T = 12$, short delay recall: $Z = -4$, long delay recall: $Z = -4$, and recognition discriminability: $Z = -3$). Finally, recent testing on standardized tests of autobiographical memory (Kopelman et al., 1990; Levine et al., 2002) confirms observations of impaired anterograde and retrograde memory for personal incidents with and without retrieval cues (Rosenbaum et al., 2004b).

Detailed structural MRI analysis of K.C.'s brain in 1996 and 2002 showed the left hemisphere to be affected to a greater extent than the right hemisphere. Focal signal abnormalities in the left hemisphere include a large lesion in left occipital-temporal-parietal cortex, affecting mostly lingual gyrus and cuneus and reaching medial retrosplenial cortex, and a lesion in left frontal-parietal cortex, undercutting postcentral gyrus and

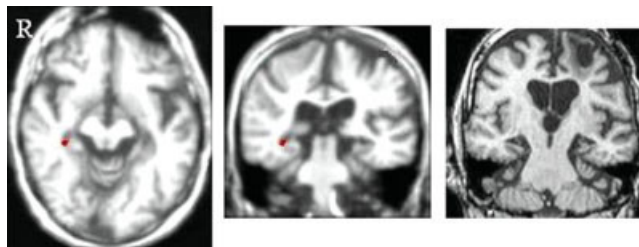


FIGURE 1. Activation of K.C.'s right hippocampus (peak voxel: 35, -28, -7; $t = 6.62$) during house recognition presented in axial (left) and coronal (middle) views. Images were thresholded at $P < 0.001$, uncorrected. High-resolution structural MRI scan in axial view for comparison to show small amount of remaining hippocampal tissue (right). [Color figure can be viewed in the online issue, which is available at www.interscience.wiley.com.]

extending across superior precentral and premotor cortex into dorsolateral prefrontal cortex. Signal abnormalities in the right hemisphere are generally limited to the precuneus. Head-size corrected quantification of tissue loss in medial-temporal and related limbic areas revealed the most prominent volume reductions to be within K.C.'s hippocampus (right, $Z = -9.8$; left, $Z = -7.8$; see Fig. 1) and parahippocampal gyrus (right, $Z = -4.8$; left, $Z = -19.1$). Disproportionate tissue loss was found to extend into other limbic structures that are closely linked neuroanatomically with the hippocampus and that have been suggested to play a role in memory, including the septal area bilaterally (right, $Z = -4$; left, $Z = -3.7$), the mammillary bodies and amygdala on the left ($Z = -3.7$ and -3.4 , respectively), caudate nuclei (right, $Z = -6.6$; left, $Z = -6.8$), and bilateral thalamus, including anterior (right, $Z = -3.1$; left, $Z = -6.2$) and posterior (right, $Z = -6.3$; left, $Z = -6.9$) portions. Given the extent of his damage, it is all the more remarkable that his remote spatial memory is so well preserved.

Control participants

K.C.'s pattern of activation during remote spatial memory tests was compared to that of 7 right-handed controls, 4 men and 3 women, matched to K.C. in terms of age (mean, 46.57 yrs; range, 44–50 yrs), education (mean, 15.86 yrs; range 15–17 yrs), and duration of residence in the neighborhood on which tasks were based (>20 yrs). Three of the controls continue to live in the neighborhood as K.C. does, whereas the others moved away from the neighborhood at the time that K.C. sustained his lesions and visit rarely if ever (i.e., no more than once a year). All participants were screened for neurological and psychiatric illness and for medications or substances known to affect brain function.

Experimental Investigation

Before experimentation, participants were informed of the scanning procedure and the nature of the tasks they would perform. All participants were required to wear glasses custom-made for use in the scanner, with corrective lenses in place for those with less than 20/20 vision uncorrected.

Design and procedure

Tasks believed to place different emphasis on the neural correlates of spatial representations were adapted from the earlier behavioral study of patient K.C. (Rosenbaum et al., 2000). These included landmark perception, landmark and house recognition, proximity judgments, distance judgments, landmark sequencing, direct-route mental navigation, blocked-route mental navigation, and vector verification. Each task run consisted of three blocks of stimuli lasting 40 s and alternating with 40 s of a baseline condition for a total of 4 min. Two scanning sequences of each task were presented within two separate scanning sessions that were at least one month apart. Task and stimulus order were counterbalanced across participants and sessions.

Because landmarks located within a smaller-scale neighborhood often do not have obvious or commonly known verbal labels, where possible, stimuli included digitally scanned color photographs taken along routes frequented by participants (tasks 1–5). Luminance and contrast were adjusted to make the images comparable within and across tasks. A baseline condition consisting of unrecognizable scrambled photographs of the same visual complexity and placed in the same positions as in the stimulus arrays were presented after three trials of a task had elapsed, and participants were asked to press right and left buttons at the same time upon viewing the stimuli to avoid placing additional demands on working memory. When the use of photographs as stimuli was less feasible, as was the case for tasks 6–8, stimuli consisted of the names of landmarks, alternating with a baseline condition in which participants viewed strings of x's while again making simultaneous button presses.

For the landmark perception and the landmark and house recognition tasks, target items were paired with distracter items taken in an unfamiliar but visually similar neighborhood, and participants selected with a corresponding right or left button press the landmark perceived as brightest for the first task or the landmark or house located in their neighborhood for the second. The distance and proximity judgment tasks involved participants deciding if the distance between target landmarks is less than or greater than 1 km or which of two landmarks is closest in distance to a third landmark, respectively, by pressing the right or left button. For the two route tasks, participants viewed the names of two familiar landmarks and a blocked street that either interferes with the route between the landmarks (blocked condition) or not (direct condition) and imagined walking along the shortest possible route, avoiding the blocked street if necessary. Finally, participants pressed a button verifying whether the orientation of a vector represents the correct direction between two specified landmarks.

Scanning and data analysis

Data were acquired with a 1.5-T Sigma scanner with a standard head coil (CV/i hardware, LX8.3 software; General Electric Medical Systems, Waukesha, WI) at Sunnybrook Health Sciences Centre. Standard high-resolution, 3D T1-weighted fast spoiled gradient echo images (TR = 12.4 ms; TE = 5.4 ms; flip angle =

35°; acquisition matrix = 256 X 192; FOV = 22 X 16.5; 124 axial slices; slice thickness = 1.4 mm) were first obtained to register functional maps against brain anatomy. Functional imaging was performed to measure brain activation by means of the blood oxygenation level-dependent (BOLD) effect with optimal contrast. Functional scans were obtained with a single-shot T2*-weighted pulse sequence with spiral readout (TR = 2000 ms; TE = 40 ms; flip angle = 80°; effective acquisition matrix = 90 X 90; FOV = 22 cm; 26 slices; slice thickness = 5.0 mm; Glover and Lai, 1998).

Repeated measures analysis of variance (ANOVA) was used for analysis of accuracy (percent correct). Image processing and analyses were performed using the Analysis of Functional Neuroimages (AFNI, version 2.25) software package (Cox, 1996). The initial 10 images before stimulus presentation, in which transient signal changes occur as the brain magnetization reaches a steady state, were excluded from all analyses. After motion correction and detrending, percent change in signal intensity with respect to baseline was analyzed using voxel-wise correlations with square-wave reference vectors that were shifted to account for the delay in hemodynamic response. The resulting individual activation images representing each task contrast of interest were transformed into Talairach coordinates and smoothed with a Gaussian filter of 6 mm FWHM to increase the signal-to-noise ratio. This was done to allow for subsequent cross-session analysis consisting of a repeated-measure ANOVA (mixed-effects design) with task as the within-subject factor.

For analysis of the data from controls, statistically significant brain activity was established using a voxel-cluster threshold technique for a whole brain corrected level of significance of less than 0.001 (voxel $P < 10^{-8}$, minimum cluster size 150 mm³). The coordinates of clusters were determined by the location corresponding to the peak t -value. Significance levels for direct statistical comparisons between the control group and individual patient were set at $P < 0.05$ (corrected). Previous hypotheses specific to the role of the hippocampus in spatial memory allowed for a more lenient uncorrected level of significance of $P < 0.001$ for this structure.

Conjunction analyses were first conducted separately for each individual task by multiplying K.C.'s activation map with that corresponding to the averaged control group, revealing brain areas that were activated in common across all participants. This produced a new activation map that only included those areas that are commonly activated beyond an overall threshold of $P < 0.001$. Areas of significant difference for each task were then identified through examination of the interaction between the controls and K.C. This was achieved by subtracting the activation maps corresponding to the control group and to K.C. to reveal regions that are differentially activated by controls, again beyond a threshold of $P < 0.001$.

Additional analyses were conducted for the house recognition task because K.C. performed poorly on this task and also activated unique MTL regions (see later). These analyses determined the frequency with which normal controls also show similar and different patterns from the group. Similar to the analyses conducted to compare K.C. with the entire control group, each con-

TABLE 1.

Brain Regions Activated in Common Across the Control Participants and Patient K.C. for the Topographical Memory Task Versus Baseline Comparisons (Conjunction; $P < 0.01$; Cluster Size > 150)

Area of activation (BA), Controls: x, y, z ; K.C.: x, y, z	Task vs. baseline						
	Landmark recognition t -score	Landmark perception t -score	Proximity t -score	Distance t -score	Sequencing t -score	Blocked route t -score	Vector t -score
R superior frontal (6/8)							
3, 12, 51	10.8		12.4	10.1	13.3	10.4	10.5
5, 13, 52	10.3		9.7	7.8	12.4	11.0	11.2
R middle frontal (6)							
30, -3, 50			12.0	8.7	11.7	9.9	9.7
28, 3, 55			8.2	8.4	15.4	10.4	6.7
L precentral (6/9)							
-40, 5, 35		7.5	11.3	9.1	10.6	8.8	9.4
-45, -5, 41		8.0	5.2	7.3	10.9	8.5	7.7
R parahipp-fusiform (36/37)							
28, -37, -13	10.1	11.3	11.7	10.6	12.0		
24, -29, -13	6.9	7.8 ^a	6.7	7.8 ^b	5.6		
L parahipp-fusiform (36/37)							
-27, -41, -14					9.16		
-24, -27, -14					14.8		
R retrosplenial (29/30)							
8, -56, 13	9.5		11.2	10.5	10.2	10.1	8.7
15, -50, 7	9.3		9.3	8.3	6.5	12.6	11.5
Medial-superior parietal (7)							
-6, -66, 53						9.2	
5, -63, 43						20.9	
L precuneus (7/19)							
-23, -69, 37			13.1	11.2			11.4
-16, -69, 29			14.3	11.2			10.8
L extrastriate (19)							
-28, -74, 25			15.0	11.5			11.3
-29, -75, 19			8.8	14.7			11.5

The Talairach coordinates are based on the peak voxel in t value. BA, Brodmann's Area according to the atlas of Talairach and Tournoux (1988). L, left; R, right.

^apeak voxel: 33, -54, -6.

^bpeak voxel: 31, -28, -4.

control participant's data were used to run conjunction and difference analyses against a group analysis that excluded that participant's data. These analyses were qualitatively compared to the ones obtained from K.C. to determine regions within the MTL that may be recruited by individual participants in addition to the ones that are significantly activated in the group and vice versa.

RESULTS

Behaviorally, participants performed equally well on all tasks of remote spatial memory (range 83–94% accuracy), with the exception of the house recognition task, on which K.C. performed at chance (~50% accuracy). With respect to underlying patterns of brain activity, however, participants were found to differ for some, but not all regions of interest (see Introduction), even if they did not differ in terms of performance.

Because no appreciable differences were found between those control participants who continued to live in the neighborhood and those who moved away long ago, their data were combined to form a single group. Results from the analyses of each task relative to its respective baseline are reported in the context of direct comparisons between K.C. and the control group, which identified regions of significant overlap and difference. Brain regions associated with tasks performed successfully by all participants are presented first, followed by those associated with the one task on which K.C. performed poorly.

Remote Memory for the Appearance and Spatial Relations of Landmarks

Common areas of activation in controls and K.C.

Table 1 shows the peak voxels of activity corresponding to patient K.C. and to the controls that lie within the boundary

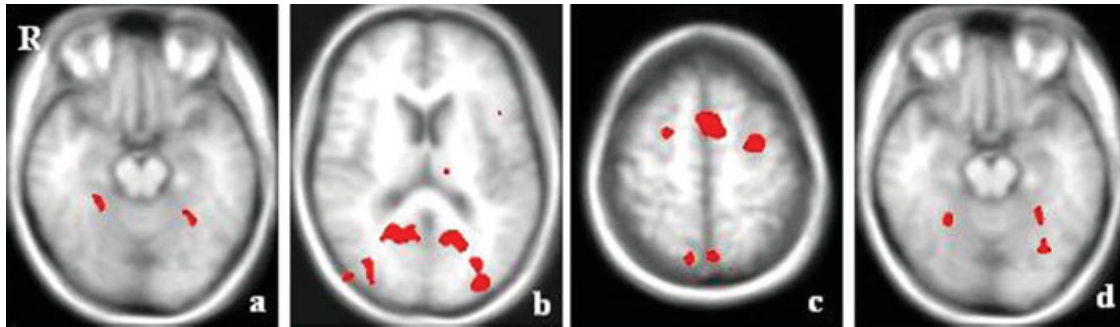


FIGURE 2. Composite scan illustrating topographical memory retrieval network of regions of interest activated in common across all tasks in control participants. The functional maps are overlaid on the averaged anatomical scans from control participants in axial views. The right hemisphere is shown on the left side of the

images. Images were thresholded at $P < 0.01$, corrected. Coordinates and t -values are listed in Table 1. [Color figure can be viewed in the online issue, which is available at www.interscience.wiley.com.]

of regions of shared activity identified by the conjunction analysis. Examination of these data revealed a network of structures engaged differentially according to the shared as well as unique demands of each task in both K.C. and the controls (Fig. 2). Participants activated in common right parahippocampal cortex [Brodmann's Area (BA) 36/37] in response to all tasks that used as stimuli photographs of landmarks (i.e., landmark recognition, landmark perception, proximity judgments, distance judgments, and landmark sequencing). However, the locus of activation differed slightly between K.C. and the controls. A more anterior region (BA 36) was active in K.C. during those tasks with a memory component (i.e., all but the landmark perception task), bordering what little remains of his hippocampus only for distance judgments. A more posterior fusiform-lingual region (BA 37/19) was active in K.C. during landmark perception. Additional left-sided activity in this region was observed in both K.C. and in the controls in response to landmark sequencing, the precise area of activation again more anterior in K.C. Also in common was activity in retrosplenial cortex (BA 29/30) during all remote spatial memory tasks, except for the direct route task, and in a region of medial-superior parietal cortex (precuneus; BA 7) during the blocked-route navigation task. A network of spatial working memory regions, including superior frontal gyrus (BA 6/8) and middle frontal

gyrus (BA 6) on the right, and precentral gyrus (BA 6/9) on the left, was active in all participants, seemingly according to the on-line spatial operations needed to perform each task. Specifically, activity was found only in superior and middle regions during the landmark recognition and landmark perception tasks, respectively, and not at all during the direct route task, all of which may be performed without reference to allocentric spatial representations. Finally, significant increases in activity shared by K.C. and the controls were found in precuneus (BA 7/19) and extrastriate cortex (BA 19) on the left during proximity judgments, distance judgments, and vector verification, the last of which likely depends on allocentric spatial representations, though the others might also. There were no areas of activity exclusive to the baseline conditions. Most notably, the hippocampus was not activated during any of these tasks in the controls or in K.C.

Different areas of activation in controls and K.C.

To assess differences between the patient and controls, direct contrasts were conducted for each task. Areas of activity unique to the healthy control participants are presented in Table 2 and Figure 3. Many of the same regions activated in common with K.C. in the right hemisphere were additionally active in the

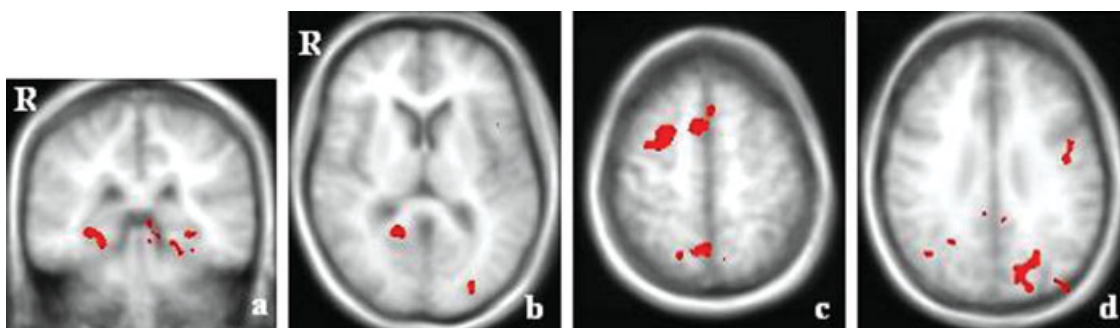


FIGURE 3. Areas of activation unique to the control participants. The functional maps are overlaid on the averaged anatomical scans from control participants in axial views. Images were

thresholded at $P < 0.001$, corrected. Coordinates and t -values are listed in Table 2. [Color figure can be viewed in the online issue, which is available at www.interscience.wiley.com.]

TABLE 2.

Areas of Activation Associated With the Topographical Memory Task Versus Baseline Comparisons in the Control Participants (Interaction; $P < 10^{-8}$; Cluster Size > 150)

Area of activation (BA): x, y, z	Task vs. baseline							
	Landmark recognition t -score	Landmark perception t -score	Proximity t -score	Distance t -score	Sequence t -score	Blocked route t -score	Direct route t -score	Vector t -score
L middle frontal (6): -26, -3, 53	10.03		12.23	11.18	13.18	15.65	10.37	12.54
L parahipp-fusiform (36/37): -28, -44, -12	8.5	7.89	10.67	8.33	9.16 ^a			
L fusiform (37): -33, -61, -19	10.66							
L retrosplenial (29/30): -13, -57, 10	10.08				10.89	12.34	9.87	10.7
R extrastriate (19): 33, -75, 18	14.29	11.68	13.6	10.44	11.67			
L med dorsal nucleus: -11, -14, 10					10.05			

The Talairach coordinates are based on the peak voxel in t value. BA, Brodmann's Area according to the atlas of Talairach and Tournoux (1988). L, left; R, right. ^aArea of shared activity.

left hemisphere for the controls. These included: (1) parahippocampal cortex (BA 36), active during the remaining tasks for which landmarks were presented visually; (2) retrosplenial cortex (BA 29/30), recruited for the recognition, sequencing, blocked and direct route, and vector tasks; and (3) middle frontal gyrus (BA 6), associated with all but the perception task. Activity in extrastriate cortex (BA 19) was also more extensive in controls, such that it was active on the left for all tasks, with additional right-sided involvement during all landmark photograph tasks. A second occipitotemporal region, located in fusiform gyrus (BA 37) just posterior to the parahippocampal activation, was engaged but only for landmark recognition. Task-specific activity was also found in the left medial dorsal nucleus of the thalamus in response to landmark sequencing.

Remote Memory for the Appearance of Houses

As indicated by the results in Table 3, despite differences in performance between the controls and K.C., right retrosplenial cortex (BA 29/30) and left extrastriate cortex (BA 19) were active in all participants. For the most part, however, controls recruited structures that were not recruited by K.C., including: (1) the contralateral homologues of retrosplenial and extrastriate cortex; (2) right parahippocampal-fusiform gyrus (BA 36/37) and bilateral fusiform gyrus (BA 37); and (3) right superior frontal and left middle frontal-precentral gyrus (BA 6). The first two sets of regions are comparable to those activated during landmark recognition, whereas the third set, which included regions of frontal cortex, is peculiar to house recognition. The latter activation may be associated with the greater difficulty participants had in distinguishing houses, rather than landmarks, from one another. As predicted, these regions were not activated in K.C. during house recognition, but the right hippocampus was (Fig. 1). Both group and individual subject analyses indicated that this was the single region of activation

found in K.C., and not in any of the controls, consistent with the idea that these houses were perceived as novel by K.C. but not by controls. It is also of interest in this regard that the same region of the right hippocampus that was activated in K.C. was also activated in a control participant (peak Talairach coordinates, x, y, z : 31, -24, -4 and 32, -27, -5, respectively) who was administered an additional perceptual task that

TABLE 3.

Common and Different Areas of Activation in Controls and K.C. Associated With the House Recognition Task Versus Baseline Comparison ($P < 0.001$; Cluster Size > 150)

Area of activation (BA)	House recognition vs. baseline	
	Controls: $x, y, z; t$ -score	K.C.: $x, y, z; t$ -score
R superior frontal (6)	3, 12, 52; 11.56	
L middle frontal-precentral (6)	34, -5, 38; 10.24	
R hippocampus ^a		35, -28, -7; 6.62
R parahipp-fusiform (36/37)	28, -37, -13; 12.72	
R fusiform (37)	32, -68, -19; 8.83	
L fusiform (37)	-32, -60, -19; 12.68	
R retrosplenial (29/30)	7, -56, 15; 11.24	15, -49, 7; 10.87
L retrosplenial (29/30)	-14, -57, 11; 9.38	
R extrastriate (19)	33, -74, 13; 14.61	
L extrastriate (19)	-31, -84, 13; 15.74	-33, -70, 21; 13.38

The Talairach coordinates are based on the peak voxel in t value. BA, Brodmann's Area according to the atlas of Talairach and Tournoux (1988). L, left; R, right. ^aLevel of significance of $P < 0.001$, uncorrected for multiple comparisons.

involved brightness judgments in response to pairs of novel landmarks.

DISCUSSION

The present fMRI study was designed to investigate how various aspects of remote spatial memory are organized in the healthy brain and following pathology and, in so doing, determine what role the hippocampus plays. For the most part, brain structures previously implicated in retrieval of topographical memory of a city core were also activated during successful retrieval of different spatial aspects of a well-known neighborhood, including those with a strong allocentric component (Maguire et al., 1997, 2006; Rosenbaum et al., 2004a; Spiers and Maguire, 2006). This network comprised posterior parietal lobe, parahippocampal cortex, retrosplenial cortex, and occipitotemporal cortex, but not the hippocampus, with activation primarily in the right hemisphere in K.C. and bilateral in controls. This pattern of brain activation contrasts with that relating to K.C.'s failure to recognize the appearance of neighborhood houses. In the latter case, activity was found in K.C.'s right hippocampus, but not in his parahippocampal cortex/fusiform gyrus, whereas the opposite was true of controls. These findings have important implications for theories relating to the neurocognitive architecture of remote topographical memory.

The Role of the Medial Temporal Lobes in Remote Spatial Memory: Is the Hippocampus Really Necessary?

A main objective of this study was to test the hypothesis that K.C.'s severely atrophic hippocampi are still viable and could support his preserved remote spatial memory. Despite successful performance, no hippocampal activity was found either in K.C. or in controls, even at more liberal thresholds. Although the medial portion of the right temporal lobe was active within the parahippocampal cortex in K.C. and in controls for all memory tests involving complex visual stimuli in the form of landmarks, no activation of the hippocampus proper was seen in any participant for any task, including those, such as vector mapping, which have a strong allocentric component and are classified as such by participants (Rosenbaum et al., 2004a). Other than activity on the border between the hippocampus and parahippocampal cortex on the right during the distance judgment task that was seen only in K.C., activity extended posteriorly into fusiform gyrus, a finding that is discussed in the next section. Additional left-sided parahippocampal activity shared among participants was revealed in response to landmark sequencing, which may be similar to the temporal sequencing or unfolding of personal episodes in memory for which the left medial temporal lobe is also involved (Burgess et al., 2001; Maguire et al., 2001).

The current study indicates that sufficiently durable, schematic representations of environments do not require hippocampal participation for their maintenance and recovery during mental or real navigation. This is consistent with a recent find-

ing of hippocampal activation only during encoding of instructions but not when altering a planned route in a virtual simulation of downtown London (Spiers and Maguire, 2006), leaving open the question as to what the role of the hippocampus is during active navigation. Although the use of VR might contribute valuable information, it might also introduce online demands that are not necessary for actual navigation, as indicated by evidence that K.C. and other individuals with hippocampal compromise can physically negotiate their way through a remotely learned environment (Milner et al., 1968; Beatty et al., 1987; Teng and Squire, 1999; Rosenbaum et al., 2000). Nevertheless, an alternative interpretation is that mental navigation tasks never activate the hippocampus because these tasks depend on schematic representations, which exist independently of the hippocampus no matter how recently they have been formed. Instead, the hippocampus may be implicated only in recently acquired "experiential" tasks, such as those that involve online navigation or viewing of detailed landmarks (see later). To test these alternatives, investigations of mental navigation based on recently encountered environments are underway in our laboratory (with M. Hirshhorn). Preliminary findings suggest hippocampal activation at liberal thresholds in individuals who have become acquainted with the environment only recently. Therefore, our results are consistent with other neuroimaging findings of hippocampal involvement in supporting spatial memories that were formed recently (Hartley et al., 2003; Iaria et al., 2003; Parslow et al., 2004; Shelton and Gabrieli, 2002; Wolbers and Büchel, 2005) but not those that were formed long ago (Maguire et al., 1997; Rosenbaum et al., 2004a; Spiers and Maguire, 2006).

It is also not known whether these remote representations can be considered to be "cognitive maps" as originally intended by O'Keefe and Nadel (1978) or whether they are simply overlearned routes (Hartley et al., 2003). However, excellent performance by K.C. and by controls alike on tasks such as proximity judgments, vector mapping, and the creation of novel detours could not be based on a mental walk along a well-rehearsed route, but instead required the flexible use of remote allocentric, topographical knowledge. Our finding that the right hippocampus was activated in K.C. and in a control on a test of (novel) house and landmark recognition lends further support to our contention that the imaging procedures were adequate to elicit hippocampal activation.

In sum, schematic spatial representations that retain the topography of an environment without its surface details, such as the appearance of houses, and that have been acquired through extensive experience, can be retained and used without the hippocampus as shown initially by lesion studies and now confirmed by functional neuroimaging. Similar results were reported by Winocur et al. (2005) for rats reared in a complex environment; they retained their ability to navigate in it normally following hippocampal lesions. In this regard, remote spatial memories are similar to remote semantic or context-free memories, which can survive hippocampal damage, though the detailed episodes or contexts in which they were acquired are lost (Tulving, 1983; Rosenbaum et al., 2001). Like remote

semantic memories, these spatial memories are represented in extra-hippocampal structures, which are discussed next.

Brain Regions Underlying Long-Term Representations of the Appearance and Spatial Relations of Landmarks

A functional system of extra-hippocampal brain areas was engaged both in K.C. and in controls across a range of spatial tasks (Aguirre and D'Esposito, 1999; Rosenbaum et al., 2004a). These included the parahippocampal-fusiform sector of occipitotemporal cortex described in the previous section, as well as retrosplenial/posterior cingulate cortex, medial-superior parietal lobule, and middle-superior frontal gyrus. Interestingly, the presence of variable amounts of tissue loss impinging on each of these regions in K.C. did not preclude their recruitment for many of the same tasks in which they are normally involved, which is all the more reason to believe that had the hippocampus been a necessary component of this remote spatial memory network, its residual tissue would have been activated (Cipolotti and Maguire, 2003).

Of this network, occipitotemporal cortex figures prominently in visual analysis of different object categories, with parahippocampal cortex most often emerging as the region specialized for landmark processing (Aguirre et al., 1998; Epstein and Kanwisher, 1998; Epstein et al., 1999; Ishai et al., 1999; Gorno-Tempini and Price, 2001). Although less certain, it is becoming increasingly apparent that there exists a further division between regions implicated in perceiving previously known and unknown landmarks under incidental conditions and those implicated in tasks requiring explicit identification of known landmarks (Aguirre and D'Esposito, 1997, 1999; Rosenbaum et al., 2004a,b). Evidence of this division was found in the present study in healthy adults who showed greater activation of a posterior left fusiform region during landmark recognition that was in addition to the more anterior bilateral parahippocampal activation present during landmark perception and mental navigation tasks in which landmarks were viewed. An opposite pattern was observed in K.C., such that right fusiform gyrus was active during landmark perception and right parahippocampal cortex was active during landmark recognition. The reason for this displacement of activity is unclear but two possibilities are offered. It may reflect the need for increased visual analysis of static topographical material following brain damage. A related alternative is that it reflects a shift in strategy, which may include increased visual analysis, to maintain high levels of performance when recognition processes are already vulnerable, as is the case for K.C. who is unable to recognize houses (see later).

Memory for the spatial properties of landmarks, apart from their appearance, may be achieved in one of a number of ways as determined by factors such as task instructions, the intentions of the navigator, or characteristics of the spatial environment (Aguirre and D'Esposito, 1999). Allocentric frameworks of landmark locations in relation to each other that remain fixed irrespective of an individual's movement are governed only in part by the medial temporal lobes (Habib and Sirigu,

1987; Bohbot et al., 1998). Extraction of orientation information appears to be the domain of retrosplenial/posterior cingulate cortex (Maguire, 2001). As such, this region was commonly activated for all remote spatial memory tests. Landmarks may also be represented in terms of an egocentric coordinate system that moves with the body during real or imagined movement along a route and that is mediated by posterior parietal cortex (Levine et al., 1985; Stark et al., 1996). Indeed, a medial-superior parietal region that has been closely linked to this viewer-dependent framework represented an area of overlap between the controls and K.C. for blocked route navigation. Planning alternate routes utilizes online computational resources to a much greater extent than imagining routes in the absence of any obstacle, and certainly as compared to judging the luminance of landmark photographs. In support of this, analyses indicated that right middle-superior frontal cortex is involved in all but the perception and direct route tasks, in line with this region's established strategic role in operating on the contents of spatial working memory held in posterior visual regions (Haxby et al., 2000). In general, however, K.C. typically activated right-sided structures, even when the same structures were engaged bilaterally in controls, consistent with the relatively more extensive damage to his left hemisphere. This lateralization of function in K.C. adds support to the widespread belief that left-sided structures play a less important role in supporting spatial cognition (Smith and Milner, 1981; Spiers et al., 2001; Burgess et al., 2002).

Neural Substrates of Impaired Remote Memory for the Appearance of Houses

A subsidiary goal of this study was to investigate the neural basis for K.C.'s profound inability to recognize the visual identity of neighborhood houses to which he has been exposed for as long as landmarks that he continues to recognize. On the basis of neuroimaging evidence (Epstein and Kanwisher, 1998), we expected controls to engage the parahippocampal cortex and related areas in extrastriate and inferior temporal cortex when recognizing houses, the same as they do when recognizing landmarks. Because K.C. can recognize landmarks but not houses, we expected a different pattern of activation when viewing houses than in controls, and than in recognizing landmarks. In particular, if the parahippocampus is needed for house recognition, then K.C. should show minimal or no activation in this region. Moreover, because all houses are equally unfamiliar to him, they will appear as novel stimuli, which typically are associated with hippocampal activation. Alternatively, the hippocampus may be needed for recognition of detailed information about houses, in which case we would expect controls to show this pattern, and not K.C. Our results were consistent with the former predictions.

Exclusive recruitment of the right hippocampus in K.C. shows that it is still possible to activate what little remains of K.C.'s hippocampus, though his performance remained at chance. K.C.'s hippocampal response may be viewed as appropriate in the context of his recognition deficit: viewing houses regarded as unfami-

liar is, in essence, the same as viewing novel, complex visual stimuli, for which the hippocampus is strongly implicated (Schacter and Wagner, 1999; Köhler et al., 2002). This interpretation is supported by preliminary results showing that both K.C. and a control participant activated the right hippocampus during a perceptual task that included only novel landmarks. In any case, activation of bilateral aspects of occipitotemporal cortex in controls, but no hippocampal activation, indicates that only the former area is needed for successful performance. The additional network of navigation-related structures elicited in all participants during landmark recognition, and in controls alone during house recognition, suggests that the mental representation of a house's appearance is fused with memory for the spatial context in which the house was experienced if the representation can be accessed (Rosenbaum et al., 2004a).

Unlike activation of the hippocampus, activation of parahippocampal cortex and fusiform gyrus is a necessary condition for recognizing the visual identity of houses experienced since long ago, as it may be for recognition and discrimination of complex visual stimuli and scenes (Murray and Bussey, 1999). This suggests that K.C.'s impairment is not simply symptomatic of his episodic memory loss for personal details but, instead, may represent a specific agnosia for houses in relation to occipitotemporal damage, a deficit that is, nevertheless, inconsequential to his ability to navigate. When considered alongside his preserved landmark recognition, it is apparent that what is left of K.C.'s parahippocampal and fusiform gyri is sufficient only for the visual processing of gross environmental features but not of their texture or details (see also Burgess et al., 2001; Lee et al., 2005a,b). It is also notable that K.C. continues to maintain a spatial representation of those houses that he is unable to recognize visually; he can describe the precise locations and the spatial relationships among neighborhood houses when given nontopographical identifying information (e.g., name of occupant).

CONCLUSION

We could find no activation of the hippocampus in control participants or in the residual, hippocampal tissue in K.C. during a variety of tests of remote spatial memory that K.C. and controls perform well, including those that have an allocentric component. These results indicate that the hippocampus is not needed for retention and retrieval of such memories, which are mediated, instead, by a network of extra-hippocampal structures. By contrast, hippocampal activation was present in K.C. as he viewed neighborhood houses that were unfamiliar to him, presumably as a result of occipitotemporal dysfunction, reflecting the role of the hippocampus in processing novel complex scenes.

The results also suggest that it may be necessary for spatial theories of hippocampal function to distinguish between the role of the hippocampus in acquisition, retention, and retrieval of recently acquired spatial memories, as compared to retention and retrieval of spatial memories of familiar environments acquired long ago and experienced extensively. The spatial

memories may not only differ in age and familiarity, but also in the nature of their representations, with recent memories being more vivid and detailed, and remote memories more schematic. Such distinctions between vivid and detailed memories on the one hand and more schematic on the other are proving useful in studying nonspatial or verbal memory, particularly memories for autobiographical and public events and people (Rosenbaum et al., 2001; Gilboa et al., 2004, 2006; Moscovitch et al., 2005; Winocur et al., 2005). The analogy with spatial memory hints that similar distinctions may underlie the differences we observed, holding the promise of a unified view of hippocampal-neocortical interaction that cuts across all memories.

Acknowledgments

The authors gratefully acknowledge K.C. and his family for their support. The authors also thank Drs. Asaf Gilboa, Randy McIntosh, and Lynn Nadel for helpful discussions of these results.

REFERENCES

- Aguirre GK, D'Esposito M. 1997. Environmental knowledge is subserved by separable dorsal/ventral neural areas. *J Neurosci* 17:2512–2518.
- Aguirre GK, D'Esposito M. 1999. Topographical disorientation: A synthesis and taxonomy. *Brain* 122:1613–1628.
- Aguirre GK, Zarahn E, D'Esposito M. 1998. An area within human ventral cortex sensitive to "building" stimuli: Evidence and implications. *Neuron* 21:373–383.
- Beatty WW, Salmon DP, Berstein N, Butters N. 1987. Remote memory in a patient with amnesia due to hypoxia. *Psychol Med* 17:657–665.
- Bohbot VD, Kalina M, Stepankova K, Spackova N, Petrides M, Nadel L. 1998. Spatial memory deficits in patients with lesions to the right hippocampus and to the right parahippocampal cortex. *Neuropsychologia* 36:1217–1238.
- Burgess N, Maguire EA, Spiers HJ, O'Keefe J. 2001. A temporoparietal and prefrontal network for retrieving the spatial context of life-like events. *Neuroimage* 14:439–453.
- Burgess N, Maguire EA, O'Keefe J. 2002. The human hippocampus and spatial and episodic memory. *Neuron* 35:625–641.
- Cipolotti L, Maguire EA. 2003. A combined neuropsychological and neuroimaging study of topographical and non-verbal memory in semantic dementia. *Neuropsychologia* 41:1148–1159.
- Cohen NJ, Eichenbaum H. 1993. *Memory, Amnesia, and the Hippocampal System*. Cambridge: MIT.
- Cox RW. 1996. AFNI: Software for analysis and visualization of functional magnetic resonance neuroimages. *Comput Biomed Res* 29:162–173.
- Epstein R, Kanwisher N. 1998. A cortical representation of the local visual environment. *Nature* 392:598–601.
- Epstein R, Harris A, Stanley D, Kanwisher N. 1999. The parahippocampal place area: Recognition, navigation, or encoding? *Neuron* 23:115–125.
- Gilboa A, Winocur G, Grady CL, Hevenor SJ, Moscovitch M. 2004. Remembering our past: Functional neuroanatomy of recollection of recent and very remote personal events. *Cereb Cortex* 14:1214–1225.
- Gilboa A, Winocur G, Rosenbaum RS, Poreh A, Gao F, Black SE, Westmacott R, Moscovitch M. 2006. Hippocampal contributions

- to recollection in retrograde and anterograde memory: Evidence from a person with bilateral fornix and septal lesions. *Hippocampus* 16:966–980.
- Glover GH, Lai S. 1998. Self-navigated spiral fMRI: Interleaved versus single-shot. *Magn Reson Med* 39:361–368.
- Gorno-Tempini ML, Price CJ. 2001. Identification of famous faces and buildings: A functional neuroimaging study of semantically unique items. *Brain* 124:2087–2097.
- Habib M, Sirigu A. 1987. Pure topographical disorientation: A definition and anatomical basis. *Cortex* 23:73–85.
- Hartley T, Maguire EA, Spiers HJ, Burgess N. 2003. The well-worn route and the path less traveled: Distinct neural bases of route following and wayfinding in humans. *Neuron* 37:877–888.
- Haxby JV, Petit L, Ungerleider LG, Courtney SM. 2000. Distinguishing the functional roles of multiple regions in distributed neural systems for visual working memory. *Neuroimage* 11:380–391.
- Iaria G, Petrides M, Dagher A, Pike B, Bohbot VD. 2003. Cognitive strategies dependent on the hippocampus and caudate nucleus in human navigation: Variability and change with practice. *J Neurosci* 23:5945–5952.
- Ishai A, Ungerleider LG, Martin A, Schouten JL, Haxby JV. 1999. Distributed representation of objects in the human ventral visual pathway. *Proc Natl Acad Sci USA* 96:9379–9384.
- Köhler S, Crane J, Milner B. 2002. Differential contributions of the parahippocampal place area and the anterior hippocampus to human memory for scenes. *Hippocampus* 12:718–723.
- Kopelman MD, Wilson BA, Baddeley AD. 1990. *The Autobiographical Memory Interview*. Suffolk: Thames Valley Test Company.
- Lee AC, Buckley MJ, Pegman SJ, Spiers H, Scahill VL, Gaffan D, Bussey TJ, Davies RR, Kapur N, Hodges JR, Graham KS. 2005a. Specialization in the medial temporal lobe for processing of objects and scenes. *Hippocampus* 15:782–797.
- Lee AC, Bussey TJ, Murray EA, Saksida LM, Epstein RA, Kapur N, Hodges JR, Graham KS. 2005b. Perceptual deficits in amnesia: Challenging the medial temporal lobe ‘mnemonic’ view. *Neuropsychologia* 43:1–11.
- Levine B, Svoboda E, Hay JF, Winocur G, Moscovitch M. 2002. Aging and autobiographical memory: Dissociating episodic from semantic retrieval. *Psychol Aging* 17:677–689.
- Levine DN, Warach J, Farah M. 1985. Two visual systems in mental imagery: Dissociation of “what” and “where” in imagery disorders due to bilateral posterior cerebral lesions. *Neurology* 35:1010–1018.
- Maguire EA. 2001. The retrosplenial contribution to human navigation: A review of lesion and neuroimaging findings. *Scand J Psychol* 42:225–238.
- Maguire EA, Frackowiak RSJ, Frith CD. 1997. Recalling routes around London: Activation of the right hippocampus in taxi drivers. *J Neurosci* 17:7103–7110.
- Maguire EA, Vargha-Khadem F, Mishkin M. 2001. The effects of bilateral hippocampal damage on fMRI regional activations and interactions during memory retrieval. *Brain* 124:1156–1170.
- Maguire EA, Nannery R, Spiers HJ. 2006. Navigation around London by a taxi driver with bilateral hippocampal lesions. *Brain* 129:2894–2907.
- Mattis S. 1988. *Dementia Rating Scale: Professional Manual*. Odessa: Psychological Assessment Resources.
- Milner B, Corkin S, Teuber HL. 1968. Further analysis of the hippocampal amnesic syndrome: 14-Year follow-up of H.M. *Neuropsychologia* 6:215–234.
- Morris RGM, Garrud P, Rawlins JNP, O’Keefe J. 1982. Place navigation impaired in rats with hippocampal lesions. *Nature* 297:681–683.
- Moscovitch M, Rosenbaum RS, Gilboa A, Addis DR, Westmacott R, Grady CL, McAndrews MP, Winocur G, Nadel L. 2005. Functional neuroanatomy of remote episodic (autobiographical), semantic and spatial memory in humans as determined by lesion and functional neuroimaging studies: A unified account based on multiple trace theory. *J Anat* 207:35–66.
- Murray EA, Bussey TJ. 1999. Perceptual-mnemonic functions of the perirhinal cortex. *Trends Cogn Sci* 3:142–151.
- Nadel L, Moscovitch M. 1997. Memory consolidation, retrograde amnesia and the HC complex. *Curr Opin Neurobiol* 7:217–227.
- O’Keefe J, Nadel L. 1978. *The Hippocampus as a Cognitive Map*. Oxford: Clarendon.
- Parslow DM, Rose D, Brooks B, Fleminger S, Gray JA, Giampietro V, Brammer MJ, Williams S, Gasston D, Andrew C, Vythelingum GN, Loannou G, Simmons A, Morris RG. 2004. Allocentric spatial memory activation of the hippocampal formation measured with fMRI. *Neuropsychologia* 18:450–461.
- Rosenbaum RS, Priselac S, Kohler S, Black SE, Gao F, Nadel L, Moscovitch M. 2000. Remote spatial memory in an amnesic person with extensive bilateral hippocampal lesions. *Nat Neurosci* 3:1044–1048.
- Rosenbaum RS, Winocur G, Moscovitch M. 2001. New views on old memories: Re-evaluating the role of the hippocampal complex. *Behav Brain Res* 127:183–197.
- Rosenbaum RS, Ziegler M, Winocur G, Grady CL, Moscovitch M. 2004a. “I have often walked down this street before.” fMRI studies on the hippocampus and other structures during mental navigation of an old environment. *Hippocampus* 14:826–835.
- Rosenbaum RS, McKinnon M, Levine B, Moscovitch M. 2004b. Visual imagery deficits, impaired strategic retrieval, or memory loss: Disentangling the nature of an amnesic person’s autobiographical memory deficit. *Neuropsychologia* 42:1619–1635.
- Rosenbaum RS, Gao F, Richards B, Black SE, Moscovitch M. 2005a. ‘Where to?’ Remote memory for spatial relations and landmark identity in former taxi drivers with Alzheimer’s disease and encephalitis. *J Cogn Neurosci* 17:446–462.
- Rosenbaum RS, Köhler S, Schacter DL, Moscovitch M, Westmacott R, Black SE, Gao F, Tulving E. 2005b. The case of K.C.: Contributions of a memory-impaired person to memory theory. *Neuropsychologia* 43:989–1021.
- Schacter DL, Wagner AD. 1999. Medial temporal lobe activations in fMRI and PET studies of episodic encoding and retrieval. *Hippocampus* 9:7–24.
- Shelton AL, Gabrieli JD. 2002. Neural correlates of encoding space from route and survey perspectives. *J Neurosci* 22:2711–2717.
- Smith ML, Milner B. 1981. The role of the right hippocampus in the recall of spatial location. *Neuropsychologia* 19:781–793.
- Spiers HJ, Maguire EA. 2006. Thoughts, behaviour, and brain dynamics during navigation in the real world. *Neuroimage* 31:1826–1840.
- Spiers HJ, Burgess N, Maguire EA, Baxendale SA, Hartley T, Thompson PJ, O’Keefe J. 2001. Unilateral temporal lobectomy patients show lateralized topographical and episodic memory deficits in a virtual reality town. *Brain* 124:2476–2489.
- Squire LR. 1992. Memory and the hippocampus: A synthesis from findings with rats, monkeys and humans. *Psychol Rev* 99: 195–231.
- Stark M, Coslett HB, Saffran EM. 1996. Impairment of an egocentric map of locations: Implications for perception and action. *Cogn Neuropsychol* 13:481–523.
- Teng E, Squire LR. 1999. Memory for places learned long ago is intact after hippocampal damage. *Nature* 400:675–677.
- Tulving E. 1983. *Elements of Episodic Memory*. Oxford: Clarendon.
- Wechsler D. 1999. *The Wechsler Abbreviated Scale of Intelligence*. New York: The Psychological Corporation.
- Westmacott R, Leach L, Freedman M, Moscovitch M. 2001. Different patterns of autobiographical memory loss in semantic dementia and medial temporal lobe amnesia: A challenge to consolidation theory. *Neurocase* 7:37–55.
- Winocur G, Moscovitch M, Fogel S, Rosenbaum RS, Sekeres M. 2005. Preserved spatial memory after hippocampal lesions: Effects of extensive experience in a complex environment. *Nat Neurosci* 8:273–275.
- Wolbers T, Büchel C. 2005. Dissociable retrosplenial and hippocampal contributions to successful formation of survey representations. *J Neurosci* 25:3333–3340.